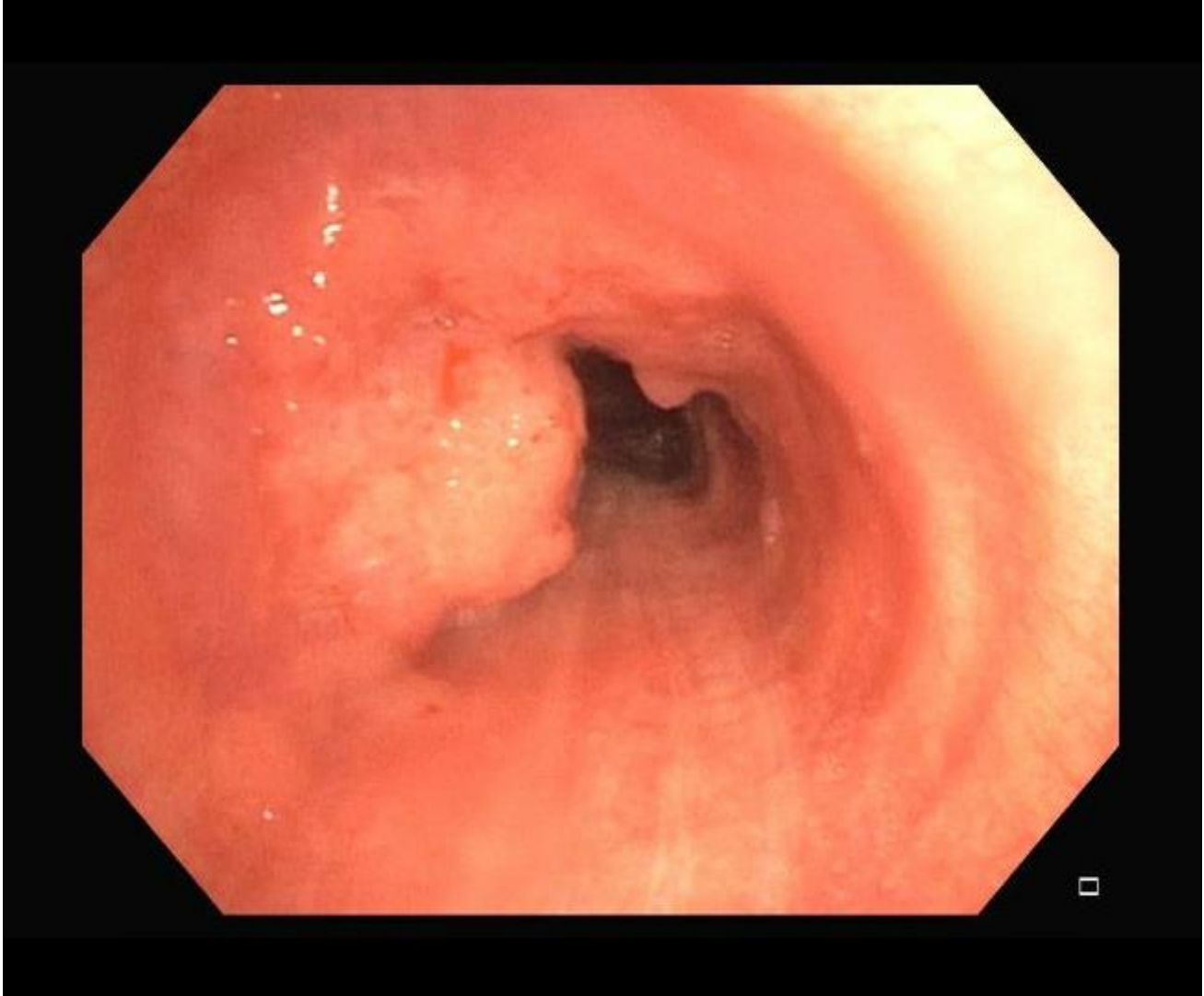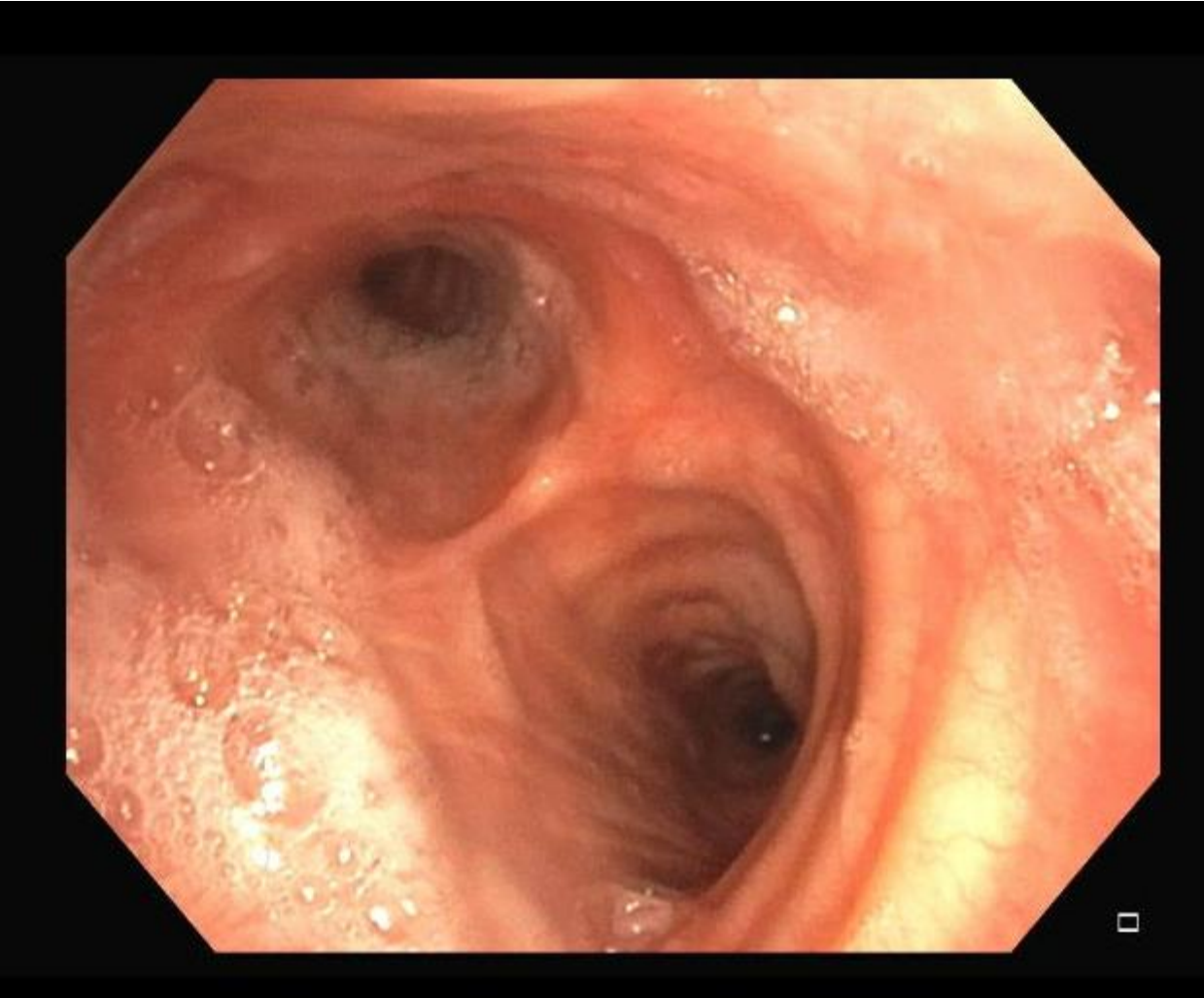
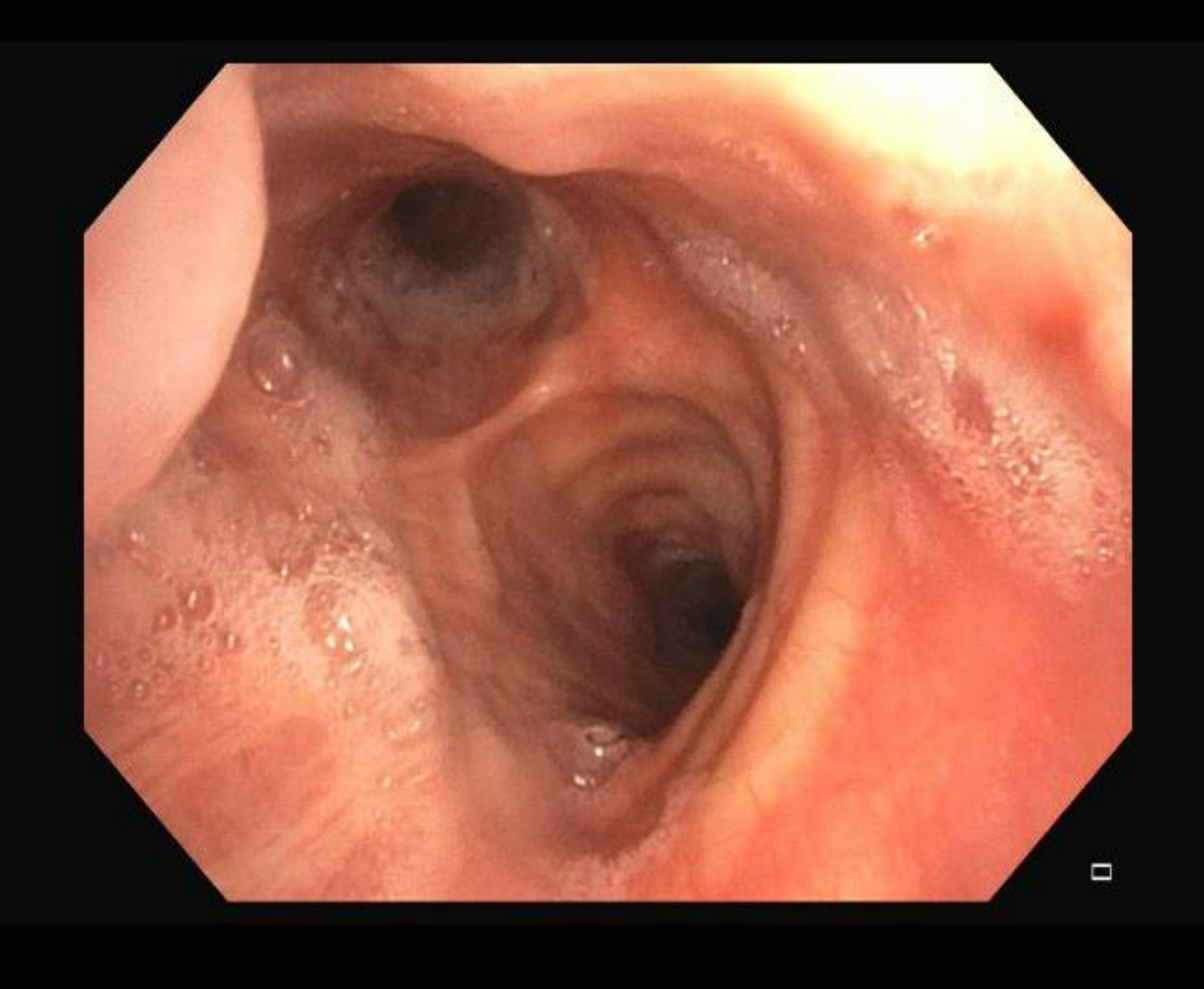


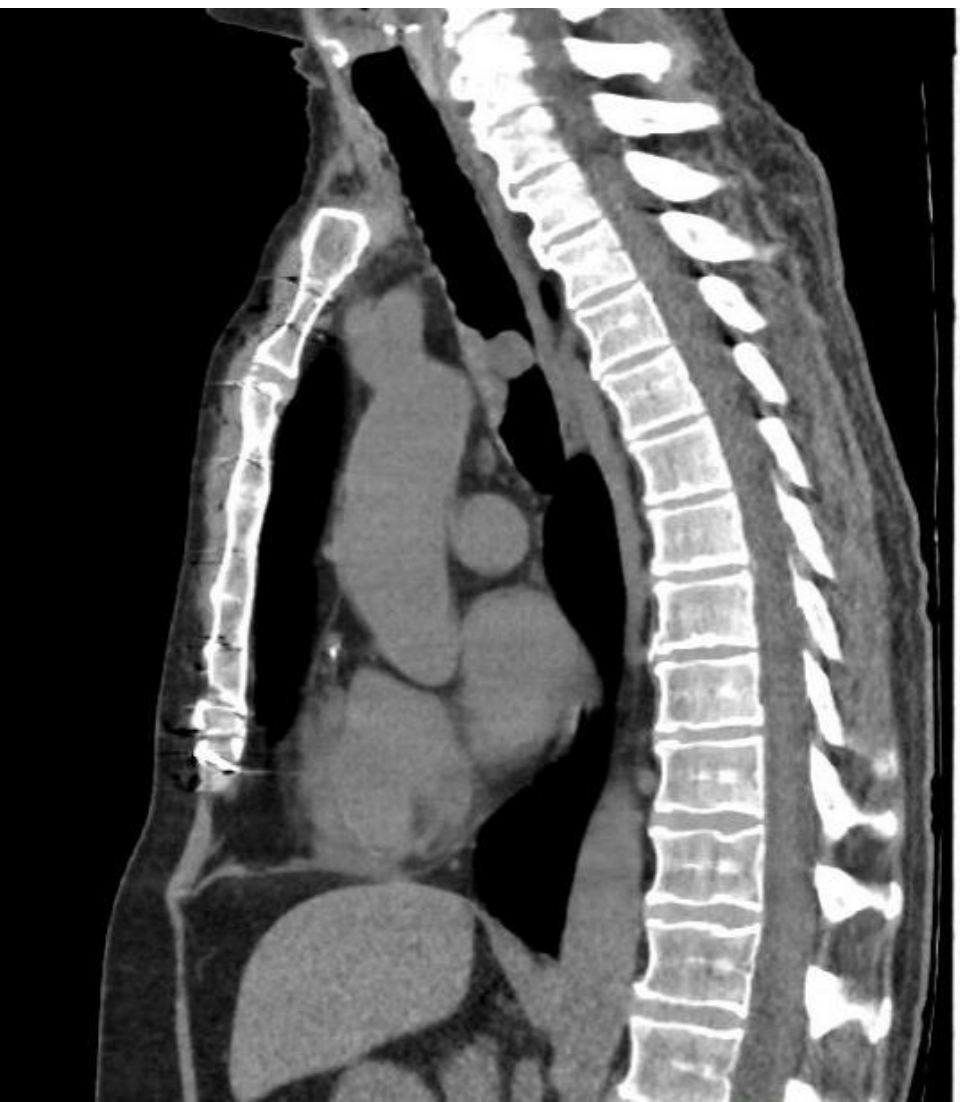Patient

- 68M with tracheal tumor
- Minor hemoptysis
- Bronchoscopy showed





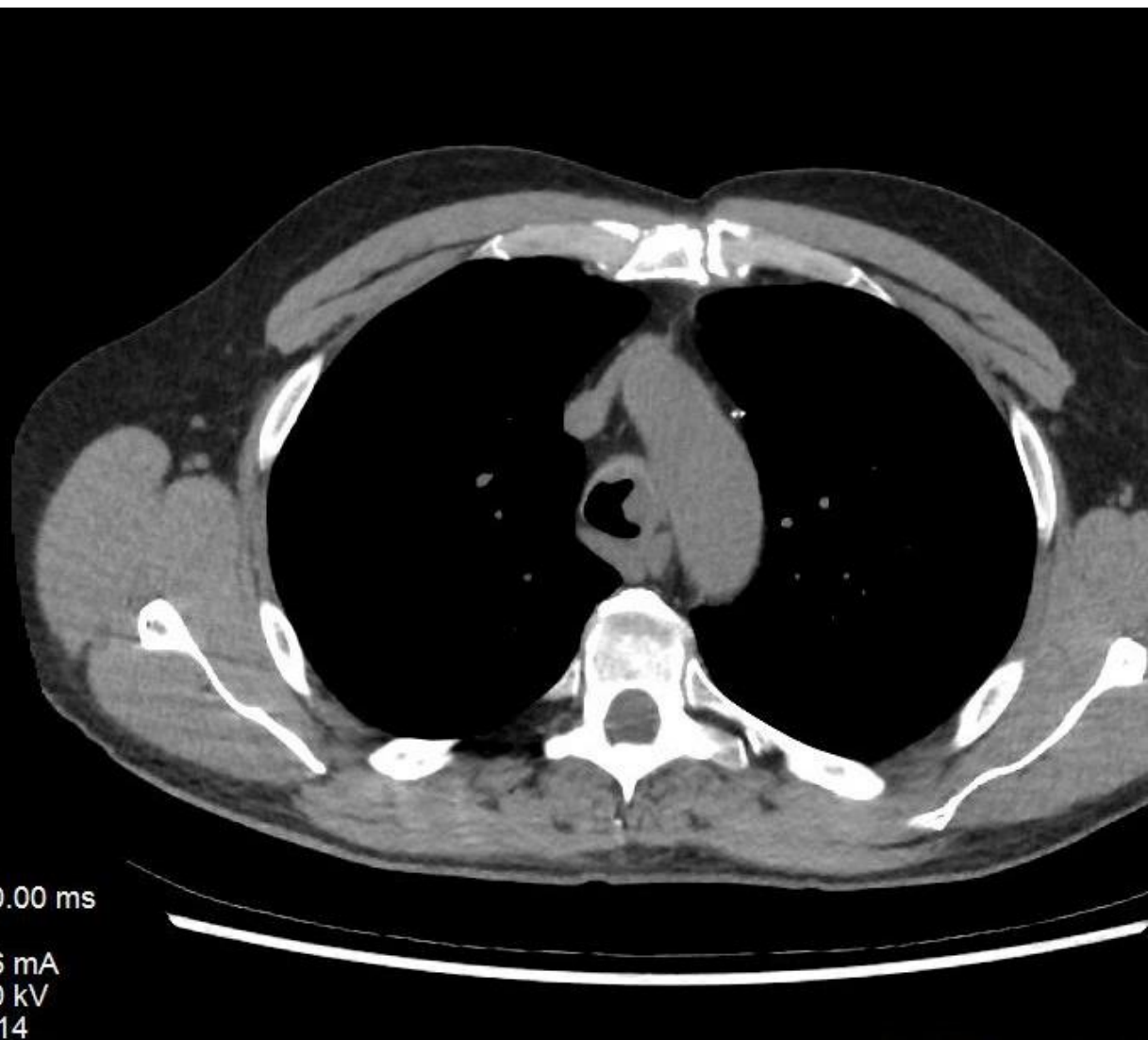




Im: 85/165
Loc: R6.5



P R



500.00 ms
0°
116 mA
120 kV
FC14

CT7-3-663

